

Local Injection of Botulinum Toxin Type A in Therapy of Focal or Segmental Dystonia

Zhang Weixi, Liang Xiuling, Chen Rong, Wang Ying

(Department of Neurology, The First Affiliated Hospital, Sun Yat-sen University, Guangzhou, Guangdong 5100080)

Abstract

Objective: To study the efficacy of botulinum a toxin injection for the treatment of hemifacial spasm, blepharospasm, Meige's syndrome and spasmodic torticollis.

Method: A total of 64 patients. (51 patients with hemifacial spasm, 10 with blepharospasm, 1 Meige's syndrome and 2 with spasmodic torticollis) were evaluated on therapeutic efficacy of multifocal facial injection.

Result: Of the 51 patients with hemifacial spasm, 20 (40%) patients were completely relieved, 30 (59%) remarkable relieved, and one didn't have improvement; of 10 patient with blepharospasm 4 were remarkable relieved, and 1 had no improvement; one patient with Meige's syndrome was partial relieved, of the 2 patients with spasmodic torticollis, 1 remarkably relieved, the other partial relieved; 97% of the patients experienced relief from spasm. Clinical observation showed marked improvement in symptoms from as few hours to the third day after injection and lasted for about 3 to 7 months. The local side effects were transient and mild; no systemic adverse and allergic reactions were noted.

Conclusion: Botulinum A toxin local injection may control hyperdystonia effectively, and ameliorate patient's abnormal face contour and posture.

Key words: Botulinum toxin; Blepharospasm; Hemifacial spasm; Meige's syndrome

All the hemifacial spasm, spasm, blepharospasm, Meige's syndrome and spasmodic torticollis are local or staged myodystonia diseases with symptoms of continue or discontinue muscular automatic spasm, convulsion, especially frequent hemifacial spasm and twinkling. Which directly affects face looking; even hinder one's work or social activities. The therapeutic way of taking oral drugs, novocaine block, acupuncture and surgical operation etc., are not much effective and easy to relapse. Since 1973, Scott ⁽¹⁾ first successfully treated the diseases with botulinum toxin, type A, the method has been used in treating hemifacial spasm, blepharospasm, Meige's syndrome and spasmodic torticollis, etc. to relieve sufferings from spasms. Following is the report of using LANTOX local injection in treating 64 patients of myodystonia for two years with significant effect.

Material and Method

Object: Totally 64 patients had myodystonia. Among these, 51 cases of one-side hemifacial spasm (30 left side and 21 right side), 10 blepharospasm (5 double side, 2 left side and 3 right side), 1 Meige's syndrome and 2 spasmodic torticollis; 28 male and 36 female; aged 18 ~ 72; the lasted course of diseases from 2 months to 20 years. All the patients were adults had no special nervous system changes, no fever and infections disease. 13 patients showed normal when inspected with head CT or MRI; 58 patients had taken stabilizing drugs; 3 patients had local alcohol novocaine block therapy, but all the treatment had no effect or disease relapsed.

Method: The product of Botulinum toxin LANTOX is a kind of lyophilized crystalline toxin, manufactured by Lanzhou Institute of Biological Products, China [(97) Weiyaozhunzi (Lan)S-01]. Three strengths of the product were 40IU/vial, 65IU/vial and 100IU/vial, kept at $-5^{\circ}\text{C} \sim 20^{\circ}\text{C}$ refrigerator. Before using, diluted to the concentration of 25IU/0.1ml with normal saline solution and injected into several points of facial muscle with 1ml syringe and 4,5# needle. Injected sites and dosage were adopted according to the area of suffering, degree of spasm and muscles' fleshiness. Injection sites for single-side blepharospasm was at 1/3 both of inner and outer side of upper and lower eyelids on suffering side, mostly by route of subcutaneous, 2 ~ 3 mm far from the eyelid-edge and orbicular muscle on temple side and injected intramuscularly into orbicularis oculi muscle 5 mm far from outer canthus. Point F was around cheekbone and point G was on cheek (Fig. 1 ~ 2). For some patients, one inject-point was increased at each of inner and outer side of eyebrow-ridge, totally 5 ~ 7 points were selected. For double side blepharospasm, the inject sites were the same, totally 10 ~ 14 points were selected. For hemifacial spasm, inject points were at zygomaticus muscle and check muscle. Orbicularis iris muscle and mentalis muscle were increased if necessary, totally 8 ~ 12 points.

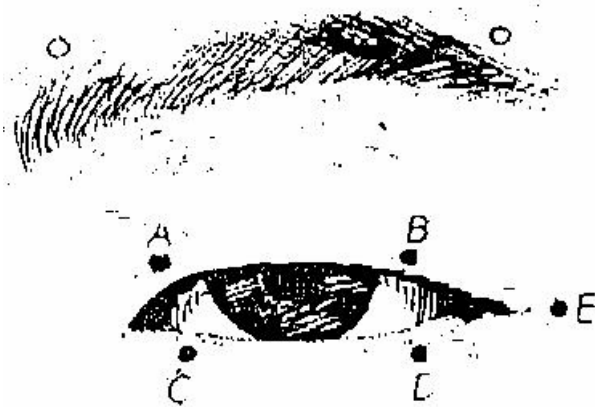


Fig.1 Injecting site of Blepharospasm



Fig. 2 Injecting site of hemifacial spasm

● : Basic point for injection; ○ : Selectable point for injection.

Blepharospasm: point A-E; Hemifacial spasm: point A-G;

(point A-D were 2 ~ 3 mm from eyelid-edge, point E was 5 mm from outer canthus, point F was near cheek bone and point G was on cheek.)

Spasmodic torticollis: 3 points at Sternocleidomastoid muscle, 5 points on the upper side of trapezius muscle, 4 points at splenius capitis and cervicis muscles. Each injection 3 ~ 4 muscles were selected according to the spasm of different individuals and 7.5 ~ 10 U for each point. If the effect was not good, then 2.5 ~ 5 U toxin was added one week later at some points. The total dosage for blepharospasm and hemifacial spasm was less than 55U each time per person and less than 200U was used within one month. For spasmodic torticollis, each time the total dosage was less than 300U. One case of Meige's syndrome was injected at the same points like side hemifacial spasm.

Judgment for Spasmodic Grade

Shorr's grades for side hemifacial spasm and blepharospasm ⁽²⁾:

Grade 0: no spasm

Grade I: twinkling increased by outside stimulation;

Grade II: mild degree of mild shaking of eyelid and facial muscle without function obstruction;

Grade III: medium degree of obvious spasm and mild function obstruction;

Grade IV: serious degree of heavy spasm and function obstruction. Eyelid turned smaller so to affect one's work and walking etc.

Complete release meant recovering from grade II ~ IV to grade 0 after the treatment, remarkable release meant recovering from grade II ~ IV to grade I ~ II and part release meant recovering from grade IV to grade III. Judgment for treatment result of spasmodic torticollis took Tsui etc ⁽³⁾ standard as a reference. Full mark is 25 points and the higher the points, the heavier the symptoms.

Result

Effect: Evaluating the result according to above standard. Among 51 patients of side hemifacial spasm, 20 completely released (40%), 30 obviously released (59%) and 1 without effect (1%); among 10 patients of blepharospasm, 5 completely released, 4 obviously released and 1 without effect; 1 case of Meige's syndrome partly released; 1 of the 2 cases of spasmodic torticollis obviously released and the other one partly released. the total effectiveness was 97%.

Effect-shown Time: 55 patients showed effect within 3 days after the injection, 7 patients within 3 ~ 7 days and the shortest one was in the same day of injection (about 6 hours after injection). The last time of hemifacial spasm was 3 ~ 7 months and 3 ~ 5 months for blepharospasm. One patient with double sides of blepharospasm had obvious effect in the second day of injection but relapsed in the third day. For those who had no relapse in 3 months after injection or had injection less than 3 months, the last time might be even longer. Among 162 injections, the dosage for first injection and second injection was the same or a little bit increased without decreased of effect. The symptom of spasm for most patients with relapse was lighter than before.

Side Effect: Only mild, transient side effect of LANTOX was seen. Some had local swollen and ecchymosis, mostly around eyes or mouth and disappeared within 1 ~ 2 weeks; 21 patients had ptosis or mild lagophthalmos; 6 patients' mouth-corner slightly turned to health side and recovered within 3 ~ 6 weeks; nasolabial groove of 8 patients turned shallower and recovered in 3 weeks; 4 patients' eyesight was unclear and 1 felt head-swollen, which relieved in 2 weeks. No allergic or serious poisonous reaction was seen. No side reaction after LANTOX injection for 1 patient with hyperthyroidism, 3 with hypertension and 1 with coronary heart disease.

Discussion

Botulinum toxin is a kind of exotoxin produced by Gram⁺ clostridium botulinum during its multiplication. 7 types toxin of A ~ G is determined by its different toxicity and antigenicity. The molecular weight of type A toxin is 150KD. One heavy chain and one light chain of which are connected by disulfide bond. Heavy chain has combining-sites with cholinergic nerve around in the property of highly selected, which may let toxin go into synapsis. Light chain has inside nerve function, which may stop releasing of Ach induced by calcium ion and produce chemical nerveless control to relax muscle spasm⁽⁴⁾. Along with further study of botulinum toxin, it has being widely used in the treatment of blepharospasm, hemifacial spasm, spasmodic torticollis, strabismus, spasmodic dysphonia, lower jaw myodystonia, limb myodystonia and twitch, etc⁽⁵⁾, especially for the therapy of local myospasm on head and face. The product has superior advantages in relaxing symptoms of those diseases for a longer period, avoiding low effect and risk caused by drug or surgical operation. In this study, effective rate of treating 64 cases with limited myodystonia was 97%. Normally, the effect can be seen within 3 days after injection. Nervous control will be recovered gradually since re-growth of axon end and formation of motor-terminal. Therefore, re-injection of the product is necessary once every 3 months. The toxin cannot pass through blood-brain screen and only operates on peripheral cholinergic

nerve end to inhibit relaxing of stimulating and self-producing Ach, so repeat injection will not produce serious side effect. Studies abroad reported that: lethal dosage of botulinum toxin to monkey was 0.5 ~ 0.7 ng/kg body weight and 1 ng/kg (about 30U/kg) to human⁽⁶⁾, while the therapeutic dose for hemifacial is only 25 ~ 50U/injection and for spasmodic torticollis is 100 ~ 200 U/injection (about 1 ~ 8 ng), that is much lower than poisonous volume. No allergic or systemic side effect was seen during the treatment except a few cases of local swollen, ecchymosis, mild ptosis, agophthalmos, drop of month corner and diplpoia, etc. Of course, antibody may produce after long-term using. Some foreign experts reported that 12 among 7000 patients, who had accepted botulinum toxin type A injection, produced antibody and 6 of them had accepted toxin volume as higher as 300 ~ 400ng. In order to avoid antibody producing, normally re-injection of that within 3 months is forbidden. Some foreign experts are trying to use other types of botulinum toxin as a supplement of type A antibody produced⁽⁷⁾.

Because the function of botulinum toxin can be enhanced by aminoglycosides antibiotics or other affecting neuromuscular transmission drugs, patient must take precautions if he is taking these drugs. Patients in the disease of heavy myasthenia, Lambert-Eaton syndrome and motoneuron must take precaution too. Up to now, it is unclear if mother's milk will contain the toxin and if it is harmful to embryo. So women in pregnant or breast-feeding should be careful to use the product.

To achieve a good effect, correct diagnosis of disease is criterion. Such as one female patient had double side blepharospasm with the symptoms of difficult to open her eyes. The symptom was relaxed the next day after botulinum toxin injection but relapsed in the third day. Her disease should be diagnosed as hysteric blepharospasm. Besides, selecting accurate injecting point and gave accurate dosage is extremely important, it requires doctor to be familiar with muscles' dissection around eye and on face. It is quite valuable to solve complicated clinical problems with electromyography to chose suitable muscles or adjust inject point with coaxial electrode-needle. Product from different manufactures and using for different individuals may have different results. But if keep to use the smallest dosage with satisfied result, side effects and antibody producing would be reduced. We found that 2.5U botulinum toxin was enough for patient with side hemifacial spasm to remove blepharospasm but not enough for mouth corner spasm or chin spasm. The reason might be orbicularis oculi muscle is smaller than chin muscle and orbicularis iris muscle. Therefore, injection dosage should be always adjusted depending on different individuals. For those with obvious and wide area spasm, inject point and inject

dosage may be increased. For old aged patients, eyelid subcutaneous injection is more effective to their loosed eyelid. It is acceptable to follow-up review the patients in the 2nd week after normal injection and give compensate injection to local missing point.

Generally speaking, the therapy to local muscle spasm with botulinum toxin is a safe, easy, economical and effective way. The effective period of which is longer and it cause only mild side effects. The using range of which would be wider and wider along with the depth of its study and complement of its using method.

Reference

1. Scott AB, Rosenbaum A, CC. Pharmacologic Weakening of Extraocular Muscles. *Invest Ophthalmol*, 1973; 12(12): 924.
2. Shorr N, Schiff SR, Kopelman J. The Use of Botulinum toxin in Blepharospasm. *Am. J. Ophthalmol*, 1985; 99(5): 542.
3. Tsui JK, Eisen A, Stoessl AJ, *et al.* Double Blind Study of Botulinum toxin in Spasmodic Torticollis. *Lancet*, 1986; 2(8501): 245.
4. Hambleton P. Clostridium Botulinum Toxins: A general Review of Involvement in Disease, Structure, Mode of Action and Preparation for Clinical Use. *J Neurol*, 1992; 239(1): 16.
5. Wan XH, Tang XF. Botulinum Toxin Type A in Therapy of Nerve System Disease. *National Neurology J China*. 1996; 29(2): 119.
6. Gill DM. Bacterial Toxins: A Table of Lethal Amounts. *Microbiol Rev*, 1982; 46(1): 86.
7. Wang YC, Tang XF. Botulinum Toxin Type A and its Clinical Using. *National Neuro-immunology and Mental Disease J China*, 1996; 3(2): 124.

(Originally published in *Journal of Practical Aesthetic and Plastic Surgery*, 2000; 11 (5): 236-238)