



REGULAR ARTICLE

Injection of botulinum toxin A in lateral pterygoid muscle as a novel method for prevention of traumatic temporomandibular joint ankylosis



Jiewen Dai ¹, Hongbo Yu ¹, Min Zhu ¹, Steve Guofang Shen ^{*}

Department of Oral & Cranio-Maxillofacial Science, Shanghai Ninth People's Hospital, Shanghai Jiao Tong University School of Medicine, Shanghai Key Laboratory of Stomatology, No.639 Zhizaoju Road, Shanghai 200011, China

Received 11 January 2014; revised 8 April 2014; accepted 14 June 2014
Available online 23 June 2014

KEYWORDS

Botulinum toxin A;
Lateral pterygoid muscle;
Prevention;
Traumatic ankylosis;
Temporomandibular joint

Abstract Temporomandibular joint (TMJ) ankylosis can restrict the mandibular movement, followed by resulting in numerous problems. To understand the mechanism of TMJ ankylosis (TMJA) and prevent the generation of TMJA is urgent necessary. Although many factors contribute to it, trauma is the most common cause of TMJA. The mechanisms of TMJA are still unclear, and the distraction osteogenesis of the lateral pterygoid muscle (LPM) may play an important role. Injection of very small amounts of botulinum toxin type A (BTA) can temporarily block the muscle's impulse and has been revealed to be an effective treatment method for many temporomandibular disorders. In this article, we make a hypothesis that LPM injection of BTA as a novel method for immobilization of mandible, followed by preventing the traumatic TMJA. Furthermore, the side effects of local injection of BTA also are minimal, temporary, reversible and self-limiting. If this strategy is validated, LPM injection of BTA will be a cost effective way to be administrated to prevent the traumatic TMJA.

© 2014 Tehran University of Medical Sciences. Published by Elsevier Ltd. All rights reserved.

Introduction

The position and intricate arrangement get the temporomandibular joint (TMJ) to be susceptible to injury during traumatic

episodes such as rear-end collisions involving cervical whiplash and other blows to the face [1]. The TMJ can be affected by trauma in a number of ways such as condylar process fractures, TMJ dislocation and fracture of the mandibular fossa [1]. The

^{*} Corresponding author. Tel.: +86 21 23271699; fax: +86 21 82263136.
E-mail address: maxillofac Surg@163.com (S.G. Shen).

¹ Jiewen Dai, Hongbo Yu and Min Zhu are co-first authors.



treatment methods of condylar process fractures have generated a great deal of discussion and controversy [2]. Many different methods, including open surgery, conservative and closed reduction by inter-maxillary fixation or splints, are applied to treat it [3,4]. For closed reduction, a 10-day period of inter-maxillary fixation to regain normal occlusion relationship and a functional mobilization schedule for three weeks is necessary. For open surgery, except for the inter-maxillary fixation in the first few days after surgery, the lateral pterygoid muscle (LPM) should be preserved because anatomic reduction of the dislocated condyle and LPM is more favorable than the liberation reduction of the fractured condyle which peeled off LPM, which may attribute to the blood supply of LPM to prevent the absorption of condyle. Unfortunately, there will be probability to cause traumatic TMJ ankylosis (TMJA) regardless of treatment method. TMJA is an intracapsular union of the disc-condyle complex to the temporal articular surface which restricts mandibular movements [5]. It may cause a great deal of problems in mastication, digestion, speech, breath, appearance and hygiene [6]. The mechanisms of traumatic TMJA are still unclear. The existing hypothesis is the organization and ossification of an intracapsular hematoma following the TMJ injury contribute to it. However, this hypothesis has not been confirmed [6,7]. Now, A study hypothesizes that the distraction osteogenesis (DO) of the LPM combining with the dislocated and damaged disc is an important factor for causing traumatic TMJA [8]. Several researches have also supported this hypothesis. A study based on the model animal showed that there was hyperplasia of new bone between the fragment and lateral stump of the condyle in sheep model which similar to clinical cases [9], and when DO of the LPM was interfered by proper treatment, such as using open-mouth plate to maintain mandibular position in the positive mouth opening in which the LPM was relaxed, or open reduction and internal fixation by which the fragment was repositioned and fixed, almost normal condylar shape would be observed after the fracture healing [10]. Based on these finds, we can hypothesize that restricting the contraction of LPM may restrict the mandible mobilization, what most important is it may be a method for prevention of traumatic TMJA. So finding a suitable strategy to restrict the

function of LPM at early stage after trauma or surgery, and is reversible at later stage, is urgently necessary.

Hypothesis

Botulinum toxin type A (BTA) are purified substances that derived from clostridium botulinum, and can block muscular nerve signals. Injection of very small amounts of BTA into specific facial muscles can block the muscle's impulse and temporarily weakens the contraction of muscle [11]. Botulinum toxin has been used since 1980 to treat many muscle disorders such as lazy eye and uncontrolled blinking. It was pioneered by dermatologic surgeons for cosmetic use in 1987. Now, BTA has been extensively used for treatment of blepharospasm, hemifacial spasm, strabismus, oromandibular dystonia, spasmodic torticollis, and spasmodic dysphonia [12]. Several studies also show that local muscle injection of BTA, including lateral pterygoid, masseter, medial pterygoid, temporalis and et al., is effective treatment for temporomandibular disorders [13,14]. Additionally, a recent study revealed that intramuscular injection of botulinum toxin as an adjunct to total joint replacement in temporomandibular joint ankylosis [15]. In this article, we hypothesize that LPM injection of BTA is a novel method for mandible immobilization, followed by inhibiting DO and preventing of traumatic TMJA. The diagrammatic representation of the hypothesis was showed in Fig. 1.

Patients with condylar fracture could be chosen for injection of BTA. LPM injection of BTA can be applied 2–3 days after intermaxillary fixation in closed reduction or after open surgery for TMJ trauma being performed. As these patients receive different drugs, doctors should consider drug interaction like aminoglycosides, cyclosporine, D-penicillamine, muscle relaxants, aminoquinolones, quinidine, magnesium sulfate, and lincosamide. Additionally, doctors also should consider contraindications of botox like hypersensitivity to botox, human albumin and pregnancy. A recommend dose is 5–10 units per time, and some studies also suggested a dose of 20–40 units per time. The dose of BTA is individualized to the patient, and many other factors such as muscle size and activity should also be taken into consideration. A 30-gauge needle is preferable and

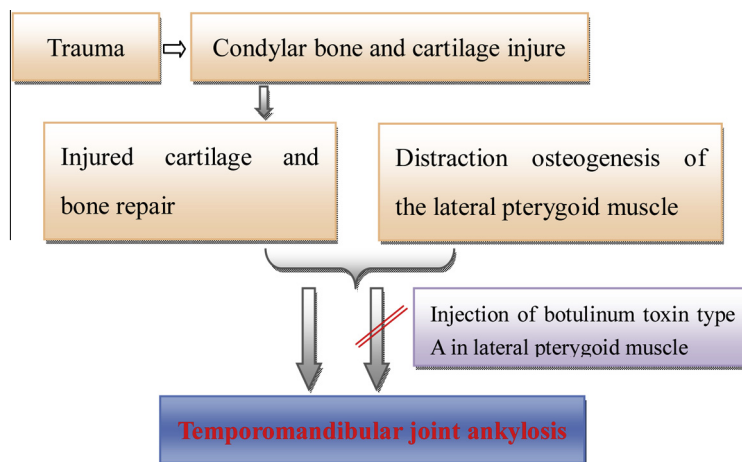


Fig. 1 Diagrammatic representation of the hypothesis. Trauma would lead to injured condylar bone and cartilage. Then the distraction osteogenesis of the lateral pterygoid muscle during the healed process may contribute to the traumatic temporomandibular joint ankylosis. We make a hypothesis that lateral pterygoid muscle injection of botulinum toxin type A as a novel method for immobilization of mandible, followed by preventing the traumatic temporomandibular joint ankylosis.

topical local anesthetic such as lidocaine applied before injection is always helpful. There are variations of these basic techniques for local injection and considerable caution should be taken while injecting in fratemporal fossa area where surrounded by the pterygoid plexus of veins. Take the extraoral approach for example [16,17], we should firstly confirm the location of the condylar process by palpation when the patient demonstrates mandibular motion and can use the electromyography (ECG) guidance for the injection. Of course, we should be careful for some patients since the anatomy of the condyle will be disturbed post-trauma. The needle is advanced at 45° posteriorly to gently engage the condylar process when inserted through the skin in the coronoid notch area. Then withdraw slightly and advance more anteriorly and slightly deeper to reach the proper position. Finally, aspiration and injection are performed. Regular follow-up for patients also is necessary, and the follow-up process at least sustain half a year. Doctors need to periodical (once every two weeks) test the function of lateral pterygoid muscle and temporomandibular joint to decide whether need to repeat the injection of BTA for some patients, or need some further therapy such as open mouth training and physiotherapy. In addition, due to infection could also induce joint ankylosis formation, we should carefully examine the patients to exclude infection related cases during this treatment procedure. Furthermore, for some patients who have previous history of BTA injection, we should take the decreased effect due to the production of antibodies into consideration.

Testing the hypothesis

The following research directions are recommended to test our hypothesis:

1. Building a traumatic temporomandibular joint ankylosis goat model.
2. Performing injection of botulinum toxin type A in lateral pterygoid muscle as a novel method for immobilization of mandible to prevent the traumatic temporomandibular joint ankylosis in this goat model, and observing the effect based on Micro CT, H&E staining and general observation.

Discussion

Trauma is the most common cause of TMJA which leads to many problems and its treatment is difficult. Management of TMJA is mainly through surgical intervention, but the results were variable and often were not satisfactory [2,18]. Prevention of traumatic ankylosis is urgently necessary, but always unresolved due to its unclear mechanisms. Based on the possible mechanism that the DO of the LPM is an important factor in causing traumatic TMJA, we suggest that LPM injection of BTA as a novel method for prevention of traumatic TMJA. The LPM acts to lower the mandible and is also essential in pulling the capsule and disc forward during mouth opening, thereby maintaining normal relationship between the TMJ disc and condyle [19]. So local injection of BTA can help to immobilize mandible and keep the TMJ disc in a normal position at early stage. A functional mobilization for three weeks after a 10-day period of intermaxillary fixation will begin, and the

paralysis of LPM will not affect the passive mouth opening exercise and masticate function due to the assistance by the digastric, mylohyoid and geniohyoid muscles. The effect of BTA can last about 4 months which is similar to the length of the time for a bone fracture to heal [11,20]. So the condylar fractures will have well healed and do not to cause ankylosis when the contraction function of LPM reverse. In addition, side effects of local injection of BTA are generally minimal, temporary, reversible, and self-limiting [21]. What most important is the BTA has been demonstrated that is effective treatment methods for temporomandibular disorders and the LPM injection are mature techniques, especially by the guidance of ECG. Compared to local anesthetic by lidocaine which need repeat injection many times due to it sustains a short time, injection of BTA once may be enough and the medical costs and infection risk greatly reduced. If this strategy is validated, the prevention of traumatic TMJ ankylosis will become reality, finally bring great hope to patients with TMJ trauma.

Overview Box.

First Question: What do we already know about the subject?

The mechanisms of traumatic temporomandibular joint ankylosis are still unclear, and the distraction osteogenesis of the lateral pterygoid muscle may play an important role. Injection of very small amounts of botulinum toxin A can temporarily block the muscle's impulse and has been revealed that is an effective treatment method for many temporomandibular disorders. Additionally, a recent study revealed that intramuscular injection of botulinum toxin as an adjunct to total joint replacement in temporomandibular joint ankylosis. Furthermore, the side effects of local injection of botulinum toxin A also are minimal, temporary, reversible and self-limiting. These finds implied that lateral pterygoid muscle injection of botulinum toxin type A may be a novel method for immobilization of mandible, followed by preventing the traumatic temporomandibular joint ankylosis.

Second Question: What does your proposed theory add to the current knowledge available, and what benefits does it have?

If this strategy is validated, lateral pterygoid muscle injection of botulinum toxin A will be a cost effective way that may be administrated to prevent traumatic ankylosis.

Third Question: Among numerous available studies, what special further study is proposed for testing the idea?

In order to evaluate the hypothesis, studies that building a traumatic temporomandibular joint ankylosis goat model is necessary. Then perform injection of botulinum toxin type A in lateral pterygoid muscle as a novel method for immobilization of mandible to prevent the traumatic temporomandibular joint ankylosis in this goat model, and observing the effect based on Micro CT, H&E staining and general observation.

Conflicts of interest statement

None declared.

Acknowledgement

This work was supported by the National Nature Science Foundation of China (No. 81300842) and Program for Innovation Research Team of Shanghai Municipal Education Commission.

References

- [1] Mitchell DA. A multicentre audit of unilateral fractures of the mandibular condyle. *Br J Oral Maxillofac Surg* 1997;35: 230–6.
- [2] Valiati R, Ibrahim D, Abreu ME, Heitz C, de Oliveira RB, Pagnoncelli RM, et al. The treatment of condylar fractures: to open or not to open? A critical review of this controversy. *Int J Med Sci* 2008;5:313–8.
- [3] De Riu G, Gamba U, Anghinoni M, Sesenna E. A comparison of open and closed treatment of condylar fractures: a change in philosophy. *Int J Oral Maxillofac Surg* 2001;30:384–9.
- [4] Simsek S, Simsek B, Abubaker AO, Laskin DM. A comparative study of mandibular fractures in the United States and Turkey. *Int J Oral Maxillofac Surg* 2007;36:395–7.
- [5] Gundlach KK. Ankylosis of the temporomandibular joint. *J Craniomaxillofac Surg* 2010;38:122–30.
- [6] Guven O. A clinical study on temporomandibular joint ankylosis. *Auris Nasus Larynx* 2000;27:27–33.
- [7] Ferretti C, Bryant R, Becker P, Lawrence C. Temporomandibular joint morphology following post-traumatic ankylosis in 26 patients. *Int J Oral Maxillofac Surg* 2005;34:376–81.
- [8] Meng FW, Zhao JL, Hu KJ, Liu YP. A new hypothesis of mechanisms of traumatic ankylosis of temporomandibular joint. *Med Hypotheses* 2009;73:92–3.
- [9] Long X, Goss AN. A sheep model of intracapsular condylar fracture. *J Oral Maxillofac Surg* 2007;65:1102–8.
- [10] Kermer C, Undt G, Rasse M. Surgical reduction and fixation of intracapsular condylar fractures. A follow up study. *Int J Oral Maxillofac Surg* 1998;27:191–4.
- [11] Aoki KR, Guyer B. Botulinum toxin type A and other botulinum toxin serotypes: a comparative review of biochemical and pharmacological actions. *Eur J Neurol* 2001;8:21–9.
- [12] Jost WH. Clinical use of botulinum toxin. *Nervenarzt* 2008;79: 9–14.
- [13] Freund B, Schwartz M, Symington JM. Botulinum toxin: new treatment for temporomandibular disorders. *Brit J Oral Max Surg* 2000;38:466–71.
- [14] Song PC, Schwartz J, Blitzer A. The emerging role of botulinum toxin in the treatment of temporomandibular disorders. *Oral Diseases* 2007;13:253–60.
- [15] Robiony M. Intramuscular injection of botulinum toxin as an adjunct to total joint replacement in temporomandibular joint ankylosis: preliminary reports. *J Oral Maxillofac Surg* 2011;69: 280–4.
- [16] Schwartz M, Freund B. Treatment of temporomandibular disorders with botulinum toxin. *Clin J Pain* 2002;18: S198–203.
- [17] Mendes RA, Upton LG. Management of dystonia of the lateral pterygoid muscle with botulinum toxin A. *Br J Oral Max Surg* 2009;47:481–3.
- [18] Vasconcelos BC, Porto GG, Bessa-Nogueira RV, Nascimento MM. Surgical treatment of temporomandibular joint ankylosis: follow-up of 15 cases and literature review. *Med Oral Patol Oral Cir Bucal* 2009;14:E34–8.
- [19] Murray GM, Bhutada M, Peck CC, Phanachet I, Sae-Lee D, Whittle T. The human lateral pterygoid muscle. *Arch Oral Biol* 2007;52:377–80.
- [20] Teixeira AC, Luz JG, Araujo VC, Araujo NS. Healing of the displaced condylar process fracture: an experimental study. *J Craniomaxillofac Surg* 1998;26:326–30.
- [21] Jankovic J, Esquenazi A, Fehlings D, Freitag F, Lang AM, Naumann M. Evidence-based review of patient-reported outcomes with botulinum toxin type A. *Clin Neuropharmacol* 2004;27:234–44.