

## REVIEW ARTICLE

Allan H. Ropper, M.D., *Editor*

## Trigeminal Neuralgia

Giorgio Cruccu, M.D., Giulia Di Stefano, M.D., Ph.D.,  
and Andrea Truini, M.D., Ph.D.

From the Department of Human Neuroscience, Sapienza University of Rome, Rome. Address reprint requests to Prof. Cruccu at Dipartimento Neuroscienze Umane, Università Sapienza di Roma, Viale Università 30, 00185 Rome, Italy, or at giorgio.cruccu@uniroma1.it.

N Engl J Med 2020;383:754-62.  
DOI: 10.1056/NEJMra1914484

Copyright © 2020 Massachusetts Medical Society.

**T**RIGEMINAL NEURALGIA, TRADITIONALLY CALLED TIC DOULOUREUX, IS A chronic neuropathic pain disorder characterized by spontaneous and elicited paroxysms of electric shock-like or stabbing pain in a region of the face. A poor quality of life and suicide in severe cases have been attributed to the disorder.<sup>1,2</sup> A classification of trigeminal neuralgia has been adopted by several professional societies and forms the basis of its description in the *International Classification of Diseases, 11th Revision (ICD-11)*.<sup>3</sup>

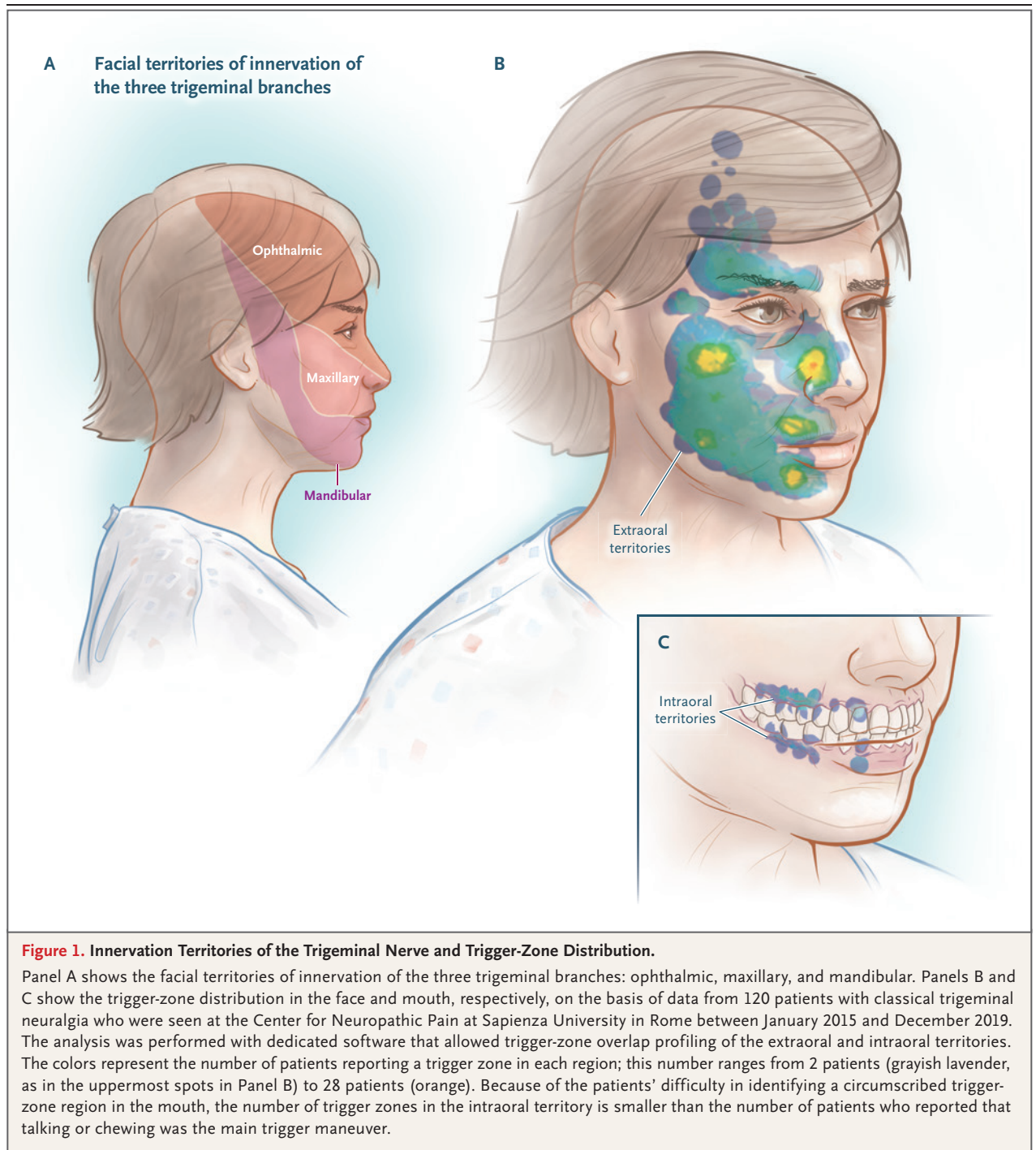
## CLINICAL CHARACTERISTICS AND DIAGNOSIS

The diagnosis of trigeminal neuralgia is clinical and is based on three main criteria: pain restricted to the territory of one or more divisions of the trigeminal nerve; paroxysms of pain that are sudden, intense, and very short (<1 second to 2 minutes, but usually a few seconds) and are described as a “shock” or an “electric sensation”; and pain triggered by innocuous stimuli on the face or intraoral trigeminal territory. Triggered paroxysmal pain is particular to trigeminal neuralgia and is reported by 91 to 99% of patients,<sup>4-6</sup> indicating that this feature may be pathognomonic of trigeminal neuralgia.<sup>3</sup>

The pain of trigeminal neuralgia most frequently affects the distribution of the second (maxillary) or third (mandibular) division of the trigeminal nerve, with the right side of the face affected more often than the left side. Bilateral trigeminal neuralgia is rare and should raise concern about facial neuralgia due to an underlying neurologic disease or a non-neurologic disorder affecting the cranium. The incidence of trigeminal neuralgia is higher among women than among men and increases with age.<sup>7</sup>

Many forms of facial pain have been conflated with trigeminal neuralgia, but they are likely to be distinct entities, sometimes subsumed under the category of “atypical facial pain” or “painful trigeminal neuropathy.” The posterior third of the scalp, the outer ear (with the exception of the tragus), and the skin overlying the angle of the mandible are not innervated by the trigeminal nerve and are not sites of pain due to trigeminal neuralgia (Fig. 1); pain in these areas suggests an alternative process.

The pain of trigeminal neuralgia may be triggered by common gestures of daily life, and the triggers are in small receptive sensory zones — for example, the touch of a napkin or tissue on the upper lip or even a breeze flowing across a sensitive area of the face. The location of the pain is not always concordant with the site of a sensory trigger. For example, stimuli in and around the lower lip may induce pain in the temple, or sensory triggers in the lateral portions of the nose may induce a shocklike pain radiating toward the forehead or upper lip. Specific trigger maneuvers from one series of patients are shown in Table 1, and the dis-



tribution of trigger zones that elicit pain are shown in Figure 1. Few patients report no triggers.

Examination for trigeminal neuralgia includes observation of the face while the patient is seated and remains completely still. With a spontaneous paroxysm of trigeminal neuralgia,

the physician may notice a blink or a small mouth movement of which the patient is unaware.<sup>4</sup> Less often, during a paroxysmal attack, forceful contraction of the facial muscles, called “tic convulsif,” may occur. Sensory examination of the face is generally unrevealing in cases of

**Table 1. Trigger Maneuvers in 120 Patients with Classical Trigeminal Neuralgia.\***

Triggers	No. of Patients (%)
<b>Activities of daily living</b>	
Talking	71 (59)
Washing face	52 (43)
Chewing	49 (41)
Brushing teeth	43 (36)
Drying face	43 (36)
Eating	23 (19)
Drinking	17 (14)
Shaving	16 (13)
Applying makeup	7 (6)
Combing hair	2 (2)
Washing hair	2 (2)
<b>Specific movements</b>	
Swallowing	13 (11)
Blowing nose	11 (9)
Gently touching face	106 (88)
Jaw movement	7 (6)
Head movement	7 (6)
Yawning	7 (6)
Flexing the trunk forward	5 (4)
Pronouncing labial letters	5 (4)
Raising voice	5 (4)
Laughing	3 (3)
Eye movement	2 (2)
Tongue movement	2 (2)

\* Data are from 120 patients seen at the Center for Neuro-pathic Pain at Sapienza University in Rome between January 2015 and December 2019.

trigeminal neuralgia, although some patients report areas of mild hypoesthesia.

#### TYPES AND CAUSES

Three types of trigeminal neuralgia have been delineated: classical, secondary, and idiopathic. The classical type, which is the most common, is caused by intracranial vascular compression of the trigeminal nerve root, as described below. The responsible vessel is usually the superior cerebellar artery, which induces morphologic changes in the adjacent trigeminal nerve root. Secondary trigeminal neuralgia, which accounts

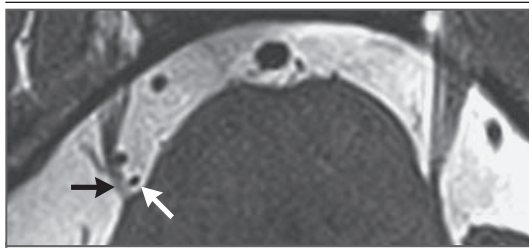
for approximately 15% of cases, is attributable to an identifiable neurologic disease such as multiple sclerosis or a tumor in the cerebellopontine angle, which alters the root entry zone of the trigeminal nerve or otherwise compresses the nerve in its extracranial course. Idiopathic trigeminal neuralgia, in which no apparent cause of nerve disturbance can be found, accounts for approximately 10% of cases.

The clinical features of classical and secondary trigeminal neuralgia are similar, although patients with secondary trigeminal neuralgia are usually younger, more likely to have sensory loss on a portion of the face, and are more likely to have bilateral pain.<sup>8</sup> Since the three forms of trigeminal neuralgia may be clinically indistinguishable, magnetic resonance imaging (MRI) with gadolinium to rule out multiple sclerosis and cerebellopontine masses is advisable at the time of the initial diagnosis. A recent study showed rare variants in genes encoding voltage-gated ion channels in patients with a family history of classical or idiopathic trigeminal neuralgia, but the frequency and clinical importance of this finding are not known.<sup>9</sup>

#### NEUROVASCULAR COMPRESSION IN CLASSICAL TRIGEMINAL NEURALGIA

Over the past several decades, the classical form of trigeminal neuralgia has been revealed through the work of Peter Jannetta and others, and the potential for cure by means of intracranial microvascular surgery has been studied. The pathophysiology is considered to be compression of the sensory portion of the trigeminal nerve, close to its root entry zone in the pons, by an adjacent small branch of the basilar artery, most often the superior cerebellar artery. However, simple contact between the nerve and a vascular structure does not appear to be adequate to cause or explain the disorder. To attribute the disorder to neurovascular compression, the anomalous vessel should ideally be shown to induce anatomical alterations in the trigeminal root, such as distortion or atrophy.<sup>5,10</sup> The most characteristic finding at operation is a small, tortuous artery or arterial loop impinging on the medial aspect of the trigeminal root at its entry zone, causing lateral dislocation, distortion, flattening, or atrophy of the trigeminal root (Fig. 2).

Neurovascular compression can be seen with



**Figure 2. Neurovascular Compression.**

An MRI scan, obtained with axial constructive interference in steady state imaging, shows neurovascular compression by a looped vessel (white arrow) at the entry zone of the trigeminal nerve root, with dislocation of the nerve root (black arrow).

the use of MRI and three-dimensional reconstruction. Imaging techniques include three-dimensional T2-weighted MRI sequences with detailed examination of the cisternal and cavernous segments of the nerve, three-dimensional time-of-flight magnetic resonance angiography for visualization of arteries, and phase-contrast MRI to display veins.<sup>11,12</sup> The specific imaging features that identify morphologic changes in the trigeminal root with certainty vary among investigators. However, several studies have suggested that microstructural changes in the nerve at sites of vascular compression can be quantified with the use of diffusion tensor imaging and tractography to disclose focal demyelination and edema,<sup>13,14</sup> although these sensitive techniques are not used in most centers, and the imaging diagnosis can be made with more conventional MRI methods. Vascular decompression may reverse these abnormalities at the trigeminal root entry zone, where the sensory portion of the nerve enters the ventral pons.<sup>13</sup>

#### PATHOPHYSIOLOGY

At its entrance into the pons, the trigeminal nerve (like all peripheral nerves) loses its Schwann cell myelin sheath, which is replaced by central myelin generated by oligodendroglia. This zone of transition is vulnerable to damage and particularly to demyelination. Vascular compression is the usual cause of demyelination at the site just before the nerve enters the pons, and multiple sclerosis is the typical cause at the site just after entry into the pons. Demyelination at these sites has been shown in neurophysiological, neuroimaging, and histologic studies.<sup>15</sup>

When the myelin sheath becomes thin enough to allow the transmembrane passage of ions in the underlying axon, the axon is not equipped to promptly pump out sodium. The resulting depolarization makes the axon hyperexcitable,<sup>10</sup> causing ectopic generation of impulses with high-frequency afterdischarges<sup>16,17</sup> (discharges that occur after termination of the stimulus) and cross-talk between fibers (called ephaptic transmission).<sup>18</sup> Histologic evidence indicates that the nerve fibers most involved in demyelination are the A- $\beta$  fibers (large, non-nociceptive fibers), which are the most susceptible to demyelination from mechanical damage or multiple sclerosis. It has been proposed that the high-frequency discharges originating at the site of demyelination along the A- $\beta$  primary afferents are redirected by brain-stem neurons to be perceived as paroxysmal pain.<sup>19</sup> Some investigators have observed excessive excitability or reductions in the volume of several cortical and subcortical cerebral areas in patients with trigeminal neuralgia,<sup>20,21</sup> but such changes are probably consequences of adaptation to chronic stimulation of these regions.<sup>21</sup>

#### TRIGEMINAL NEURALGIA WITH CONTINUOUS PAIN

Although paroxysmal facial pain is the hallmark of trigeminal neuralgia, 24 to 49% of patients<sup>4,22</sup> report continuous or long-lasting pain between paroxysmal attacks. Background fluctuating pain, with a distribution that is consistent with that of the paroxysmal pain, is described as burning, throbbing, or aching.<sup>23</sup> Trigeminal neuralgia characterized by this symptom, regardless of the cause, was previously classified as trigeminal neuralgia type 2 or atypical trigeminal neuralgia<sup>24,25</sup> and is now classified as trigeminal neuralgia with concomitant continuous pain.<sup>26</sup> The mechanism underlying continuous pain is different from the mechanism underlying paroxysmal pain, as suggested by the lesser degree of alleviation of continuous pain, as compared with paroxysmal pain, after treatment with sodium-channel blockers or microvascular decompression.<sup>22,27</sup> The pathophysiological link between the two pain entities is uncertain. Progressive damage of the nerve root and central sensitization mechanisms have been hypothesized.<sup>28,29</sup> Burning, throbbing, or aching pain is probably



mediated by impairment of C fibers (unmyelinated sensory axons that transmit impulses slowly), as shown in other neuropathic pain conditions.<sup>19</sup> Loss of C fibers in the trigeminal sensory root may cause abnormal spontaneous activity in second-order neurons in the brain stem as a result of denervation supersensitivity of exposed postsynaptic membranes to neurotransmitters.<sup>19</sup> The previous notion that continuous pain develops as a result of long-standing trigeminal neuralgia is not supported by more recent data.<sup>22</sup>

#### SECONDARY TRIGEMINAL NEURALGIA

In 15% of patients with typical pain attacks, trigeminal neuralgia is caused by multiple sclerosis or by benign tumors in the cerebellopontine angle.<sup>30</sup> The risk of trigeminal neuralgia is increased by a factor of 20 among patients with multiple sclerosis, as compared with the general population,<sup>7</sup> with a prevalence of 2 to 5% among patients with multiple sclerosis.<sup>31,32</sup> Multiple sclerosis–related trigeminal neuralgia has been attributed to a demyelinating plaque in the fascicle of the trigeminal nerve as it courses through the ventral pons.<sup>33</sup> Occasionally, trigeminal neuralgia is manifested as a clinically isolated syndrome in patients with multiple sclerosis; the age at the onset of multiple sclerosis is higher for these patients than for those who do not have trigeminal neuralgia.<sup>34</sup> One neuroimaging study has shown an association between neurovascular compression and multiple sclerosis–related trigeminal neuralgia, suggesting that they may coexist and be additive.<sup>35</sup> The frequency of this dual mechanism is not known, but it has implications for treatment. Pharmacologic treatment of the pain of trigeminal neuralgia in patients with multiple sclerosis is challenging because of side effects of medications, worsening of symptoms of multiple sclerosis such as fatigue and ataxia, and limited evidence of its effectiveness in such patients.<sup>36,37</sup> Case series indicate that surgical procedures to reduce vascular compression tend to be less effective in patients with trigeminal neuralgia caused by multiple sclerosis than in patients with classical trigeminal neuralgia.<sup>38,39</sup>

Tumors in the cerebellopontine angle that compress the trigeminal nerve root and cause trigeminal neuralgia include acoustic neuromas,

meningiomas, epidermoid cysts, and cholesteatomas.<sup>40</sup> Curiously, trigeminal neuromas (which are rare) have not been associated with trigeminal neuralgia. In an analysis of data from four studies that included 243 patients with trigeminal neuralgia, tumors were the cause in 20 patients (8%).<sup>30</sup> Compression of the trigeminal nerve by tumors induces focal demyelination of the trigeminal nerve root, triggering the same generation of high-frequency discharges in denuded axons that occurs in vascular compression of the nerve.<sup>40</sup> Infiltrative malignant tumors can also cause axonal degeneration, resulting in hypoesthesia in regions of the face and persistent pain.

Trigeminal neuropathies due to trauma and rheumatologic diseases such as systemic lupus erythematosus and scleroderma can be manifested as paroxysmal pain mimicking trigeminal neuralgia, but these associations are infrequent. Trigeminal neuropathy in these instances may start with unilateral paroxysmal pain, but bilateral sensory loss soon develops over regions of the face with ongoing pain, a disorder often termed trigeminal neuritis. Facial trauma, dental procedures, or maxillofacial surgery may damage trigeminal nerve branches, causing paroxysmal stabbing, electric shock–like, or burning pain. However, the pain attacks have a longer duration than trigeminal neuralgia paroxysms, and most patients also describe severe ongoing pain without sensory trigger zones. Isolated idiopathic trigeminal neuropathy, a benign bilateral, symmetric, purely sensory trigeminal neuropathy, and facial-onset sensory motor neuronopathy, a more serious progressive disease, may also initially be manifested as unilateral paroxysmal facial pain.<sup>41</sup>

Trigeminal reflex testing has been used as a neurophysiological technique to detect trigeminal nerve damage.<sup>8</sup> This diagnostic test is useful in patients who cannot undergo MRI or to detect demyelination and neuropathies mimicking trigeminal neuralgia (see the Supplementary Appendix, available with the full text of this article at NEJM.org).

#### TREATMENT

##### MEDICAL TREATMENT

The anticonvulsant agents carbamazepine, in doses of approximately 200 to 1200 mg per day, and oxcarbazepine (300 to 1800 mg per day) have been considered the first-choice treatments

for control of paroxysmal pain in patients with trigeminal neuralgia, regardless of the cause.<sup>8</sup> Although these treatments are not supported by data from randomized, controlled trials, clinicians consider the drugs to be highly effective, with meaningful pain control in almost 90% of patients.<sup>8</sup> The treatment effect is proposed to be related to blockade of voltage-gated sodium channels, resulting in stabilization of hyperexcited neuronal membranes and inhibition of repetitive firing.<sup>16</sup> However, clinical improvement is often offset by side effects, including dizziness, diplopia, ataxia, and elevated aminotransferase levels, one or more of which may lead to treatment withdrawal in 23% of patients.<sup>42</sup> Oxcarbazepine may have fewer side effects and a lower potential for drug–drug interaction than carbamazepine,<sup>43</sup> though it may be discontinued because of excessive central nervous system depression or dose-related hyponatremia.<sup>10</sup> Other, more selective sodium-channel blockers are under development. Contraindications to the use of sodium-channel blockers include cardiac conduction problems and allergic reactions, with a high degree of cross-reactivity (40 to 80%) with aromatic antiepileptic drugs.<sup>44</sup> Carbamazepine and oxcarbazepine reduce the high-frequency discharges that characterize the electric shock–like paroxysms, but the effect of these drugs on concomitant continuous pain is usually limited.<sup>22,37</sup>

Gabapentin, pregabalin, and antidepressant agents, which have been shown to be effective in the treatment of other neuropathic conditions characterized by continuous pain, may be tried as additional agents along with oxcarbazepine or carbamazepine. Clinical experience suggests that gabapentin may have a lesser effect on trigeminal neuralgia than carbamazepine and oxcarbazepine but is associated with a lower incidence of adverse events and can be attempted either as monotherapy or as add-on therapy, if it is associated with an acceptable side-effect profile, including in patients with multiple sclerosis.<sup>8,37</sup> If a course of medical treatment is ineffective or associated with unacceptable side effects, surgical decompression of the trigeminal nerve may be considered.

#### LOCAL SURGICAL PROCEDURES

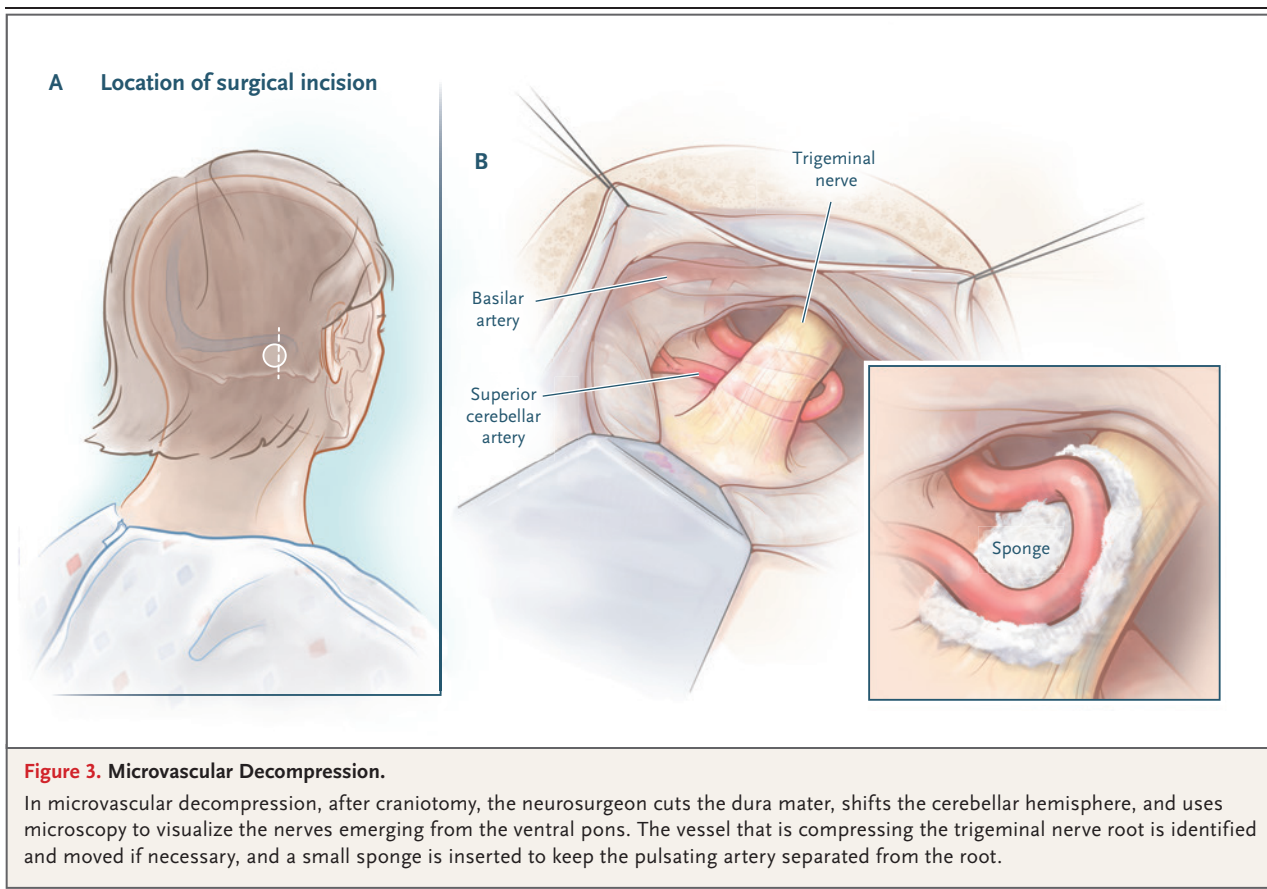
Although surgical procedures are effective in reducing the severity and frequency of attacks of trigeminal neuralgia in appropriately chosen pa-

tients, this type of surgery is generally undertaken only if standard doses of medications are not sufficient to control symptoms or if side effects prevent continued use.

One group of surgical interventions, now used infrequently, involves peripheral blockade of trigeminal nerve branches at their emergence from the facial bones by means of neurectomy, alcohol injections, or induction of radiofrequency lesions or cryolesions. The purpose of these procedures is to produce an area of anesthesia on the face that corresponds to the distribution of the damaged nerve. However, the benefit of such treatments has not been adequately supported by trials,<sup>8</sup> and the procedures often led to anesthesia dolorosa (intense pain in the area of sensory loss).

A second group of interventions seeks to percutaneously damage the trigeminal ganglion in Meckel's cave or exiting branches of the ganglion at the base of the skull by means of radiofrequency thermocoagulation,<sup>45</sup> chemical destruction through injection of glycerol,<sup>46</sup> or mechanical compression through balloon inflation.<sup>47</sup> Radiofrequency thermocoagulation preferentially damages small-diameter pain fibers. To prevent corneal deafferentation and resultant keratitis, the electrode is aimed so as to avoid damaging the first division of the trigeminal nerve. Balloon compression and glycerol injection preferentially damage large myelinated fibers. Pain relief is immediate with these techniques and has been reported in the following percentages of cases: 68% (range, 55 to 80) with balloon compression (follow-up, 4.2 to 10.7 years), 58% (range, 26 to 82) with radiofrequency thermocoagulation (follow-up, 3.0 to 9.3 years), and 28% (range, 19 to 58) with glycerol rhizolysis (follow-up, 4.5 to 8.0 years).<sup>8</sup> Trigeminal sensory deficits are usually transient with balloon compression and glycerol injection and are more severe and longer lasting after radiofrequency thermocoagulation.

Generating a lesion of the trigeminal root with a gamma knife is a more recently introduced procedure and is supported by several studies. A challenge of this procedure is accurate identification of the coordinates of the trigeminal root before their entrance into the pons, where the radiation beams must be collimated to avoid damaging the pons. In contrast to the immediate pain relief associated with percutaneously caused lesions of the trigeminal ganglion,



the pain-relieving effect of gamma-knife stereotactic radiosurgery takes 6 to 8 weeks to develop. Approximately 24 to 71% of patients report continued pain relief 1 to 2 years after undergoing the procedure, and 33 to 56% report continued pain relief at 4 to 5 years.<sup>8</sup> Facial numbness has been reported in 16% of patients, whereas anesthesia dolorosa is virtually absent. A meta-analysis showed that approximately 34% of patients do not have pain relief at 1 year and require repeat procedures.<sup>48</sup>

#### MICROVASCULAR DECOMPRESSION

Microvascular decompression has become the surgical procedure that is now favored for most cases of trigeminal neuralgia that do not respond to medication. The neurosurgeon identifies the vessel that is compressing the trigeminal nerve root, moves it from under the nerve to over the nerve if necessary (Fig. 3), and typically inserts a small sponge to keep the pulsating artery separated from the nerve root. In about 11% of patients, the surgeon does not find neu-

rovascular compression<sup>5</sup> or finds a mere contact, with no apparent nerve compression. In these cases, the surgeon usually inserts the separating sponge anyway, even though the rate of failure is higher than it is when distortion of the nerve root is identified. This problem underscores the advantage of using established MRI criteria to identify morphologic changes in the trigeminal root.<sup>5</sup>

Despite the lack of high-level evidence-based data,<sup>49,50</sup> meta-analyses have suggested that microvascular decompression is the most efficacious surgical intervention for classical trigeminal neuralgia. At 1 to 2 years after undergoing the procedure, 68 to 88% of patients have pain relief, and 61 to 80% have pain relief at 4 to 5 years.<sup>8</sup> The average mortality associated with the surgery is 0.3%. Cerebrospinal fluid leaks occur in 2.0% of patients, brain-stem infarctions or hematomas in 0.6%, and meningitis in 0.4%. Sensory loss in part or all of the trigeminal nerve sensory distribution on the face occurs in 2.9% of patients. The most troubling long-term compli-

cation, although rare (incidence, 1.8%), is ipsilateral hearing loss.<sup>8</sup>

There is insufficient evidence to support or refute the effectiveness of surgical management of trigeminal neuralgia in patients with multiple sclerosis, although patients with multiple sclerosis who have drug-resistant trigeminal neuralgia may be offered microvascular decompression.<sup>36</sup> However, both percutaneous ganglion lesions and gamma-knife lesions have also been reported to have good outcomes in patients with multiple sclerosis.<sup>39</sup>

## CONCLUSIONS

Trigeminal neuralgia is an extremely painful condition that can be difficult to diagnose and treat. Carbamazepine and oxcarbazepine constitute the first-line medical treatment. However,

many patients have side effects, and those who have concomitant continuous pain are less likely to have a good response to treatment. Diagnostic tests, particularly neuroimaging, are useful for identifying the cause and for identifying patients with trigeminal neuralgia due to major neurologic diseases and patients in whom small branches of the basilar artery compress the proximal nerve. The application of standardized MRI criteria for identifying neurovascular compression may aid in selecting patients for microvascular decompression.

Dr. Cruccu reports receiving fees for educational activities from Alfasigma Italy and advisory fees from Grünenthal, Lilly, and Angelini Italy; and Dr. Truini, receiving consulting fees from Eliem Therapeutics, Angelini Italy, and Grünenthal. No other potential conflict of interest relevant to this article was reported.

Disclosure forms provided by the authors are available with the full text of this article at NEJM.org.

## REFERENCES

- Freeman R, Edwards R, Baron R, et al. AAPT diagnostic criteria for peripheral neuropathic pain: focal and segmental disorders. *J Pain* 2019;20:369-93.
- Zakrzewska JM, Wu J, Mon-Williams M, Phillips N, Pavitt SH. Evaluating the impact of trigeminal neuralgia. *Pain* 2017; 158:1166-74.
- Scholz J, Finnerup NB, Attal N, et al. The IASP classification of chronic pain for ICD-11: chronic neuropathic pain. *Pain* 2019;160:53-9.
- Di Stefano G, Maarbjerg S, Nurmikko T, Truini A, Cruccu G. Triggering trigeminal neuralgia. *Cephalalgia* 2018;38:1049-56.
- Cruccu G, Finnerup NB, Jensen TS, et al. Trigeminal neuralgia: new classification and diagnostic grading for practice and research. *Neurology* 2016;87:220-8.
- Maarbjerg S, Gozalov A, Olesen J, Bendtsen L. Trigeminal neuralgia — a prospective systematic study of clinical characteristics in 158 patients. *Headache* 2014;54:1574-82.
- Katusic S, Beard CM, Bergstralh E, Kurland LT. Incidence and clinical features of trigeminal neuralgia, Rochester, Minnesota, 1945-1984. *Ann Neurol* 1990; 27:89-95.
- Bendtsen L, Zakrzewska JM, Abbott J, et al. European Academy of Neurology guideline on trigeminal neuralgia. *Eur J Neurol* 2019;26:831-49.
- Di Stefano G, Yuan JH, Cruccu G, Waxman SG, Dib-Hajj SD, Truini A. Familial trigeminal neuralgia — a systematic clinical study with a genomic screen of the neuronal electrogenisome. *Cephalalgia* 2020;40:767-77.
- Cruccu G. Trigeminal neuralgia. *Continuum (Minneapolis)* 2017;23(2, Selected Topics in Outpatient Neurology):396-420.
- Leal PR, Hermier M, Souza MA, Cristino-Filho G, Froment JC, Sindou M. Visualization of vascular compression of the trigeminal nerve with high-resolution 3T MRI: a prospective study comparing preoperative imaging analysis to surgical findings in 40 consecutive patients who underwent microvascular decompression for trigeminal neuralgia. *Neurosurgery* 2011;69:15-25.
- Shimizu M, Imai H, Kagoshima K, Umezawa E, Shimizu T, Yoshimoto Y. Detection of compression vessels in trigeminal neuralgia by surface-rendering three-dimensional reconstruction of 1.5- and 3.0-T magnetic resonance imaging. *World Neurosurg* 2013;80:378-85.
- DeSouza DD, Davis KD, Hodaie M. Reversal of insular and microstructural nerve abnormalities following effective surgical treatment for trigeminal neuralgia. *Pain* 2015;156:1112-23.
- Leal PR, Roch JA, Hermier M, Souza MA, Cristino-Filho G, Sindou M. Structural abnormalities of the trigeminal root revealed by diffusion tensor imaging in patients with trigeminal neuralgia caused by neurovascular compression: a prospective, double-blind, controlled study. *Pain* 2011;152:2357-64.
- Peker S, Kurtkaya O, Uzün I, Pamir MN. Microanatomy of the central myelin-peripheral myelin transition zone of the trigeminal nerve. *Neurosurgery* 2006;59: 354-9.
- Burchiel KJ. Abnormal impulse generation in focally demyelinated trigeminal roots. *J Neurosurg* 1980;53:674-83.
- Waxman SG, Brill MH. Conduction through demyelinated plaques in multiple sclerosis: computer simulations of facilitation by short internodes. *J Neurol Neurosurg Psychiatry* 1978;41:408-16.
- Devor M, Amir R, Rappaport ZH. Pathophysiology of trigeminal neuralgia: the ignition hypothesis. *Clin J Pain* 2002; 18:4-13.
- Truini A, Garcia-Larrea L, Cruccu G. Reappraising neuropathic pain in humans — how symptoms help disclose mechanisms. *Nat Rev Neurol* 2013;9:572-82.
- Wang Y, Cao D-Y, Remeniuk B, Krimmel S, Seminowicz DA, Zhang M. Altered brain structure and function associated with sensory and affective components of classic trigeminal neuralgia. *Pain* 2017; 158:1561-70.
- Obermann M, Rodriguez-Raecke R, Naegel S, et al. Gray matter volume reduction reflects chronic pain in trigeminal neuralgia. *Neuroimage* 2013;74:352-8.
- Maarbjerg S, Gozalov A, Olesen J, Bendtsen L. Concomitant persistent pain in classical trigeminal neuralgia — evidence for different subtypes. *Headache* 2014;54:1173-83.
- Rasmussen P. Facial pain. II. A prospective survey of 1052 patients with a view of: character of the attacks, onset, course, and character of pain. *Acta Neurochir (Wien)* 1990;107:121-8.
- Nurmikko TJ, Eldridge PR. Trigeminal neuralgia — pathophysiology, diagnosis and current treatment. *Br J Anaesth* 2001;87:117-32.



25. Burchiel KJ. A new classification for facial pain. *Neurosurgery* 2003;53:1164-6.
26. Headache Classification Committee of the International Headache Society (IHS). The International Classification of Headache Disorders, 3rd edition. *Cephalalgia* 2018;38:1-211.
27. Sindou M, Leston J, Howeydy T, Decullier E, Chapuis F. Micro-vascular decompression for primary trigeminal neuralgia (typical or atypical): long-term effectiveness on pain; prospective study with survival analysis in a consecutive series of 362 patients. *Acta Neurochir (Wien)* 2006;148:1235-45.
28. Burchiel KJ, Slavin KV. On the natural history of trigeminal neuralgia. *Neurosurgery* 2000;46:152-4.
29. Obermann M, Yoon MS, Ese D, et al. Impaired trigeminal nociceptive processing in patients with trigeminal neuralgia. *Neurology* 2007;69:835-41.
30. Gronseth G, Cruccu G, Alksne J, et al. Practice parameter: the diagnostic evaluation and treatment of trigeminal neuralgia (an evidence-based review): report of the Quality Standards Subcommittee of the American Academy of Neurology and the European Federation of Neurological Societies. *Neurology* 2008;71:1183-90.
31. Svendsen KB, Jensen TS, Overvad K, Hansen HJ, Koch-Henriksen N, Bach FW. Pain in patients with multiple sclerosis: a population-based study. *Arch Neurol* 2003;60:1089-94.
32. O'Connor AB, Schwid SR, Herrmann DN, Markman JD, Dworkin RH. Pain associated with multiple sclerosis: systematic review and proposed classification. *Pain* 2008;137:96-111.
33. Love S, Coakham HB. Trigeminal neuralgia: pathology and pathogenesis. *Brain* 2001;124:2347-60.
34. Cruccu G, Biasiotta A, Di Rezze S, et al. Trigeminal neuralgia and pain related to multiple sclerosis. *Pain* 2009;143:186-91.
35. Polman CH, Reingold SC, Banwell B, et al. Diagnostic criteria for multiple sclerosis: 2010 revisions to the McDonald Criteria. *Ann Neurol* 2011;69:292-302.
36. Truini A, Prosperini L, Calistri V, et al. A dual concurrent mechanism explains trigeminal neuralgia in patients with multiple sclerosis. *Neurology* 2016;86:2094-9.
37. Truini A, Barbanti P, Pozzilli C, Cruccu G. A mechanism-based classification of pain in multiple sclerosis. *J Neurol* 2013;260:351-67.
38. Di Stefano G, Truini A, Cruccu G. Current and innovative pharmacological options to treat typical and atypical trigeminal neuralgia. *Drugs* 2018;78:1433-42.
39. Broggi G, Ferroli P, Franzini A, et al. Operative findings and outcomes of microvascular decompression for trigeminal neuralgia in 35 patients affected by multiple sclerosis. *Neurosurgery* 2004;55:830-8.
40. Mohammad-Mohammadi A, Recinos PF, Lee JH, Elson P, Barnett GH. Surgical outcomes of trigeminal neuralgia in patients with multiple sclerosis. *Neurosurgery* 2013;73:941-50.
41. Puca A, Meglio M. Typical trigeminal neuralgia associated with posterior cranial fossa tumors. *Ital J Neurol Sci* 1993;14:549-52.
42. Cruccu G, Pennisi EM, Antonini G, et al. Trigeminal isolated sensory neuropathy (TISN) and FOSMN syndrome: despite a dissimilar disease course do they share common pathophysiological mechanisms? *BMC Neurol* 2014;14:248-56.
43. Di Stefano G, La Cesa S, Truini A, Cruccu G. Natural history and outcome of 200 outpatients with classical trigeminal neuralgia treated with carbamazepine or oxcarbazepine in a tertiary centre for neuropathic pain. *J Headache Pain* 2014;15:34.
44. Beydoun A. Safety and efficacy of oxcarbazepine: results of randomized, double-blind trials. *Pharmacotherapy* 2000;20:152S-158S.
45. Błaszczyk B, Lasoń W, Czuczwar SJ. Antiepileptic drugs and adverse skin reactions: an update. *Pharmacol Rep* 2015;67:426-34.
46. Sweet WH, Wepsic JG. Controlled thermocoagulation of trigeminal ganglion and rootlets for differential destruction of pain fibers. 1. Trigeminal neuralgia. *J Neurosurg* 1974;40:143-56.
47. Håkanson S. Trigeminal neuralgia treated by the injection of glycerol into the trigeminal cistern. *Neurosurgery* 1981;9:638-46.
48. Mullan S, Lichtor T. Percutaneous microcompression of the trigeminal ganglion for trigeminal neuralgia. *J Neurosurg* 1983;59:1007-12.
49. Tuleasca C, Carron R, Resseguier N, et al. Repeat Gamma Knife surgery for recurrent trigeminal neuralgia: long-term outcomes and systematic review. *J Neurosurg* 2014;121:Suppl:210-21.
50. Zakrzewska JM, Akram H. Neurosurgical interventions for the treatment of classical trigeminal neuralgia. *Cochrane Database Syst Rev* 2011;9:CD007312.

Copyright © 2020 Massachusetts Medical Society.

#### IMAGES IN CLINICAL MEDICINE

The *Journal* welcomes consideration of new submissions for Images in Clinical Medicine. Instructions for authors and procedures for submissions can be found on the *Journal's* website at NEJM.org. At the discretion of the editor, images that are accepted for publication may appear in the print version of the *Journal*, the electronic version, or both.